

# Descemet Stripping Automated Endothelial Keratoplasty for Endothelial Decompensation in Buphthalmos

JACQUELINE BELTZ, SILVANA MADI, PAOLO SANTORUM, VINCENZO SCORCIA, AND MASSIMO BUSIN

- **PURPOSE:** To report the results of Descemet stripping automated endothelial keratoplasty (DSAEK) to treat endothelial failure in eyes with buphthalmos.

- **DESIGN:** Prospective interventional case series.

- **METHODS:** All buphthalmic eyes with endothelial failure undergoing DSAEK by the same surgeon (M.B.) between March 2007 and January 2012 were included. Outcome measures included best spectacle-corrected visual acuity (BSCVA), refraction, and endothelial cell loss (assessed 6, 12, 24, 36, and 48 months postoperatively). Standardized DSAEK was performed in all cases, with minor modifications in phakic and aphakic eyes. Other outcomes included comparisons to penetrating keratoplasty (PK) published results and comparisons to visual outcomes in DSAEK for other indications.

- **RESULTS:** There were 14 transplants performed in 12 eyes (11 patients). Mean age was 34.9 years (range 15–54 years). The average follow-up was  $21.7 \pm 13.8$  months (range 6–48 months). At last follow-up examination, BSCVA had improved in 11 of 13 cases, with a logMAR average value  $\pm$  standard deviation of  $0.74 \pm 0.66$  from the preoperative value of  $2.07 \pm 0.80$ . Eleven eyes reached Snellen acuity of 20/200 or better, and 5 eyes reached 20/40 or better. Mean endothelial cell loss was  $40.5\% \pm 8.9\%$  (range 23.7%–53.1%). Complications included graft detachment ( $n = 2$ ), glaucoma progression ( $n = 1$ ), and late endothelial failure ( $n = 1$ ). All complications were managed successfully either by repeat DSAEK ( $n = 2$ ), rebubbling ( $n = 1$ ), or cyclocryocoagulation ( $n = 1$ ).

- **CONCLUSIONS:** DSAEK may be performed safely and effectively in buphthalmic eyes, with comparable results to outcomes after PK. Visual outcomes are not substantially different after DSAEK for this indication compared to DSAEK for other indications. (Am J Ophthalmol 2013;156:608–615. © 2013 by Elsevier Inc. All rights reserved.)

Accepted for publication Apr 18, 2013.

From Villa Igea Hospital, Department of Ophthalmology, Forlì, Italy (J.B., S.M., P.S., V.S., M.B.); Centre For Eye Research Australia, Royal Victorian Eye and Ear Hospital, Melbourne, Australia (J.B.); Alexandria University, Department of Ophthalmology, Alexandria, Egypt (S.M.); Central Regional Hospital, Department of Ophthalmology, Bolzano, Italy (P.S.); and University of Magna Graecia, Department of Ophthalmology, Catanzaro, Italy (V.S.).

Inquiries to Massimo Busin, Villa Igea Hospital, Department of Ophthalmology, Viale Gramsci 42, 47122 Forlì, Italy; e-mail: [mbusin@yahoo.com](mailto:mbusin@yahoo.com)

ENDOTHELIAL DYSFUNCTION IS RELATIVELY COMMON in buphthalmos: the high intraocular pressure (IOP) results in stretching of the sclera and cornea, damaging the Descemet membrane (DM) and the endothelial layer, resulting in breaks and subsequent formation of Haab striae.<sup>1</sup> More importantly, multiple intraocular surgeries are often required throughout the life of these young patients to manage the glaucoma and other associated pathologies, further contributing to the progressive decline of endothelial cell density.<sup>2</sup>

Traditionally, endothelial failure in patients with buphthalmos has been treated with penetrating keratoplasty (PK),<sup>2</sup> but visual prognosis of this surgical approach is guarded<sup>3</sup> because of comorbidities (ie, advanced glaucomatous optic neuropathy and amblyopia) and the higher-than-normal intraoperative complication and postoperative failure rates.

During the past decade, Descemet stripping automated endothelial keratoplasty (DSAEK) has been established as a successful treatment for endothelial failure in Fuchs endothelial dystrophy or pseudophakic bullous keratopathy.<sup>4,5</sup> However, to date, only 1 case of DSAEK for the treatment of buphthalmos has been reported; this may reflect on the reluctance among surgeons to perform a relatively new procedure in eyes that have a rare and often complex condition.<sup>6</sup>

We report herein the results of the first prospective case series of eyes with buphthalmos with endothelial failure that underwent DSAEK; we further report on a modified surgical technique for these challenging cases.

## METHODS

THIS PROSPECTIVE STUDY, UNDERTAKEN TO EVALUATE THE outcomes of DSAEK for endothelial failure in the setting of buphthalmos, was approved by the University of Magna Graecia Institutional Review Board on November 27, 2006 (Study number 107/06). The research protocol adhered to the tenets of the 1964 Declaration of Helsinki for clinical research. All patients undergoing surgery or their legally responsible guardians (if patients were not of age to provide their own legal consent) provided informed consent to participate in this research study, and provided informed consent regarding the risks related to the presence of buphthalmos.

All patients scheduled for DSAEK for endothelial failure in the setting of buphthalmos between March 1, 2007 and

December 31, 2011 were included (n = 11 patients/12 eyes). All surgeries were performed by 1 surgeon (M.B.). A standard spreadsheet program was used to collect and analyze data pertaining to the visual results and survival of the transplants.

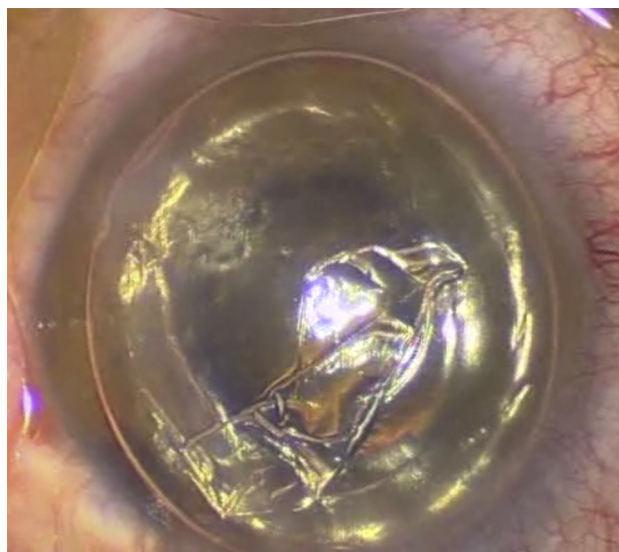
A complete ophthalmic history, including previous ocular surgeries, lenticular status, medical and surgical management of glaucoma, and date of onset of corneal decompensation was obtained for each patient. All patients underwent a complete ophthalmologic examination including slit-lamp examination, best spectacle-corrected visual acuity (BSCVA), manifest refraction, applanation tonometry, funduscopy, and B-scan ultrasound (if required) preoperatively and again at 6, 12, 24, 36, and 48 months after DSAEK. Low visual acuity and/or poor visualization prevented visual field testing or optic nerve head assessment before patients underwent DSAEK. Of the 12 eyes, 5 were phakic, 4 were aphakic, and 3 were pseudophakic with a posterior chamber IOL already in place.

Baseline donor endothelial cell density was measured by the provider eye bank by means of fixed frame technique at 100 $\times$  magnification by specular microscopy (mean of 5 different counts). Postoperative endothelial cell density was measured with automated noncontact specular microscopy (EM-3000; Tomey GmbH, Erlangen, Germany), beginning at the 6-month follow-up.

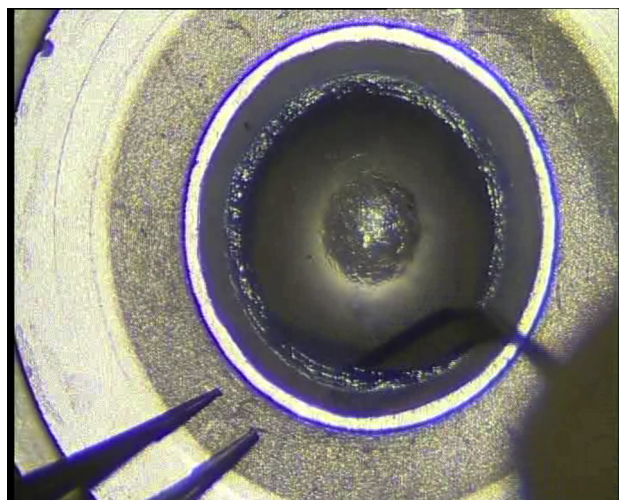
- **SURGICAL TECHNIQUE:** Surgery was performed under peribulbar anesthesia in 10 of the 12 eyes (50% mixture of lidocaine 2% and bupivacaine 0.5%). The remaining 2 eyes (both eyes of the same 15-year-old boy) had surgery performed under general anesthesia, with additional peribulbar anesthesia administered at the start of the case.

All eyes underwent a standardized DSAEK with the surgeon sitting at the 12 o'clock position, following the technique published previously.<sup>7</sup> DM was removed under air starting at the site of the Haab striae, which peeled off, showing no attachment to the overlying stroma (Figure 1). An inferior peripheral iridotomy was performed in all cases, even though a complete air fill was not expected to last in eyes with previous filtering surgery. In all cases, the increased size of the recipient cornea, the difficult intraoperative visualization, and the presence of the natural lens prompted changes as described in detail below.

Because the recipient corneas were enlarged as a result of buphthalmos, the donor graft size was increased to 9.5-10.5 mm to allow approximately 1 mm between the edge of the donor tissue and the corneoscleral limbus, as is typical in other DSAEK procedures. In each case, donor tissue was mounted on the artificial anterior chamber of the ALTK system (Moria, Antony, France) and then dissected with a single microkeratome pass. After discarding the anterior lamella, a round, sharp microfeather blade (Feather, Osaka, Japan) was used to manually dissect the peripheral cornea from the base of the keratectomy up to the edge of the artificial anterior chamber for the entire 360 degrees (Figure 2), thereby including the corneoscleral limbus. The dissected



**FIGURE 1.** Descemet stripping automated endothelial keratoplasty for endothelial decompensation in buphthalmos. Intraoperative image of removal of Descemet membrane under air starting at the site of Haab striae; Descemet membrane peels off easily with no attachment to the overlying stroma.



**FIGURE 2.** Descemet stripping automated endothelial keratoplasty for endothelial decompensation in buphthalmos. Intraoperative image of manual dissection of the peripheral donor cornea from the base of the keratectomy to the edge of the artificial anterior chamber lid for 360 degrees, reaching into the corneoscleral limbus.

rim was excised with corneal scissors while the tissue was still mounted on the artificial anterior chamber. The circumference of the dissected surface was then marked with trypan blue, and the donor tissue was punched to the desired size. We ensured proper centration to avoid peripheral nondissected tissue of uneven thickness.

In the aphakic cases, the absence of a barrier between the anterior chamber and the vitreous cavity, coupled with the poor visualization that was caused by severe and chronic corneal edema, mandated the use of a transcorneal suture (10-0 prolene) to fixate the donor tissue to the recipient temporal cornea in the periphery (Figure 3). This technique was first described by Patel and associates,<sup>8</sup> whereby a temporal attachment is obtained between donor and host to be used intraoperatively, and as a reference point for air reinjection when requiring rebubbling. Each aphakic eye underwent 4 full-thickness corneal venting incisions in the host stroma. Price and Price<sup>9</sup> first described this method as a means to help drain the interface fluid that could not be removed by air tamponade.

In the phakic cases, incision sites were shifted superiorly by about 1 clock hour to eliminate the risk of passing the surgical instruments across the pupil over the unprotected crystalline lens, thus minimizing the possibility of surgically induced cataract formation. This method has been described in more detail previously.<sup>10</sup>

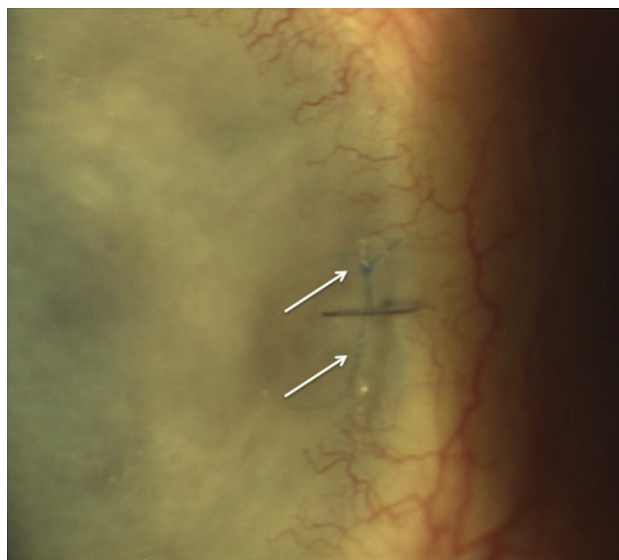Postoperatively, all patients were instructed to remain in a supine position for 2 hours and were then examined with the slit lamp. When no aqueous was present in the anterior chamber or its level was below the inferior iridotomy, some air was removed through 1 of the side entries.

If a graft detached, air was reinjected without delay; in the eyes with a temporal fixation suture, a paracentesis was created beneath the location of the suture. When necessary, wounds were resutured to ensure adequate air tamponade.

Postoperatively, all patients were given topical tobramycin 0.3% / dexamethasone 0.2% suspension combination therapy (Tobradex, Fort Worth, Texas, USA) every 2 hours for 2 weeks, then every 3 hours for 2 additional weeks. Treatment was switched to dexamethasone 0.1% (Luxazone, Allergan SpA, Rome, Italy) in a tapering regimen: 4 times daily for 1 month, to 3 times daily for a subsequent month, to twice daily in the third month, and then once daily indefinitely unless the patient was phakic or a steroid responder, in which case the steroid drops were ceased after a further 1 month. All sutures were removed 4-6 weeks post surgery. Patients continued their regular glaucoma regimens, modified as needed.

## RESULTS

THE STUDY GROUP CONSISTED OF 14 DSAEK PROCEDURES IN 12 eyes of 11 patients. Mean age was  $34.9 \pm 9.7$  years (range, 15-54 years). All patients had developed corneal edema in late childhood or early adulthood. Preoperatively, all patients had diffuse corneal edema, with increased maximum corneal diameter with or without Haab striae. Despite multiple ocular surgeries, none of the corneas exhibited neovascularization (Figure 4).



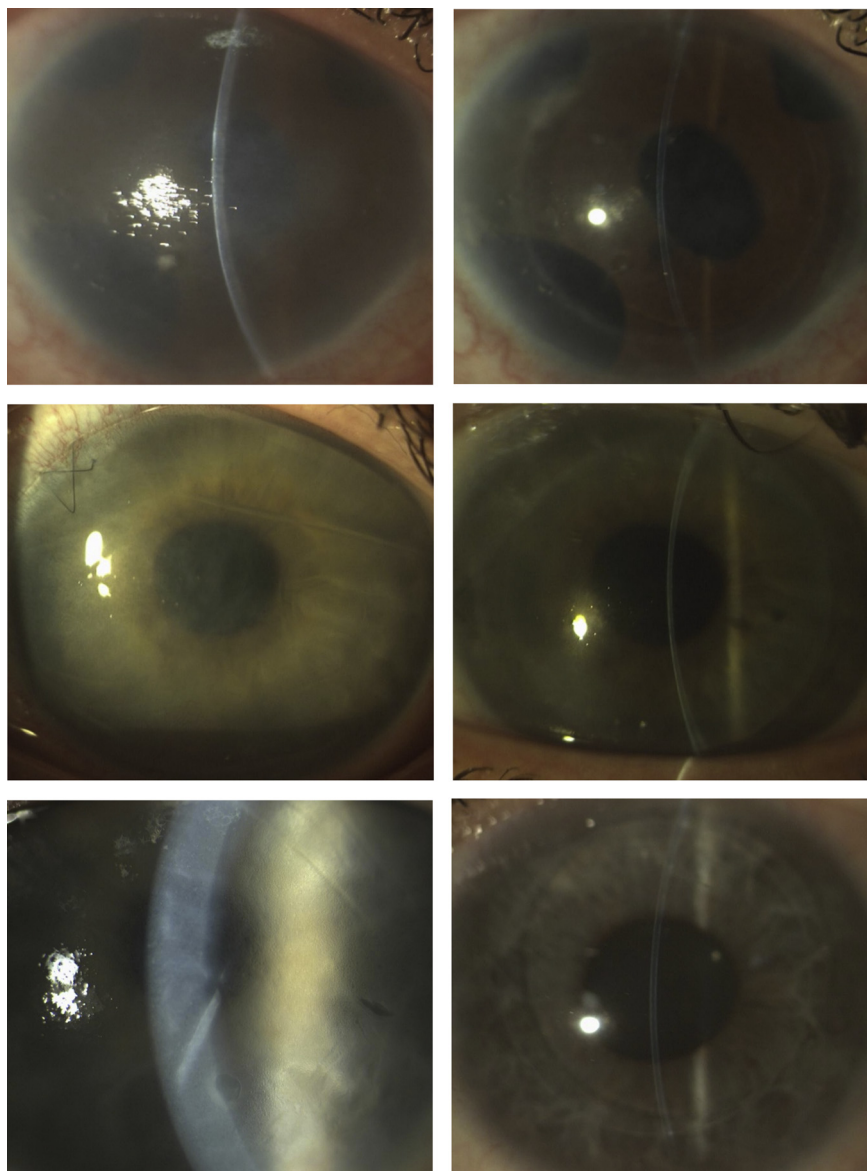
**FIGURE 3.** Transcorneal fixation of donor tissue for Descemet stripping automated endothelial keratoplasty. Early postoperative slit-lamp appearance of the transscleral 10-0 prolene suture (arrows) in an aphakic buphthalmic eye.

Five eyes were phakic (1 with cataract), 4 were aphakic, and 3 were pseudophakic with a posterior chamber intraocular lens. All but 2 eyes in this series had a varying degree of glaucomatous optic neuropathy. No eyes had nystagmus, relative afferent pupillary defect, or strabismus. Three eyes had amblyopia. Seven eyes had previous trabeculectomy (Table).

Uneventful DSAEK was performed in all cases. One case required double air injection and 1 case required multiple air injections because of graft dislocation occurring within 2 days of surgery. In the case with multiple repeat injections of air, the graft was exchanged. Histologic analysis revealed the presence of a peripheral gutter between a sickle of thick undissected tissue and the microkeratome-dissected surface, with inclusion of surface epithelium (Figure 5). It is conceivable that both the concavity of the tissue and the presence of epithelium in the interface caused detachment in this area as soon as part of the air was reabsorbed and its tamping effect was lost. This case underwent successful repeat DSAEK at 1 month after the initial surgery, and the patient's cornea subsequently cleared quickly. The first, unsuccessful surgery in this patient has been excluded from statistical analysis of the outcomes. The results of both surgeries performed in the eye with late failure are considered separately in the Table. The average follow-up in this series was  $21.7 \pm 13.8$  months (range, 6-48 months). All corneas (with exclusion of the 1 with primary failure) were clear by 1 month after successful attachment of the graft.

The majority of preoperative BSCVA was  $<20/200$ ; 1 patient had a preoperative BSCVA of 20/70 and another patient had a preoperative BSCVA of 20/60. At last follow-up, BSCVA improved in 11 of 13 cases (84.6%),





**FIGURE 4.** (Left column) Preoperative and (Right column) late (3-10 months after surgery) Descemet stripping automated endothelial keratoplasty slit-lamp appearance of an aphakic eye of a 15-year-old patient (top), a pseudophakic eye of a 36-year-old patient (middle), and a phakic eye of a 30-year-old patient (bottom). In all cases, the graft is perfectly attached, and the cornea has cleared completely.

was unchanged in 2 of 13 cases (15.4%), and did not worsen in any case. Postoperative BSCVA was 20/400 or better in 11 of 13 cases (84.6%) and 20/40 or better in 5 of 13 cases (38.5%). In 1 case the patient's vision improved from counting fingers preoperatively to 20/16 postoperatively. Postoperative visual results are detailed in the [Table](#).

Mean endothelial cell loss was  $40.5\% \pm 8.9\%$  (range, 23.7%-53.1%) from a mean donor tissue endothelial cell count of 2667 cells/mm<sup>2</sup> (range 2200-3300). There were no cases of pupillary block in this series, and to date, glaucoma has remained controlled in 11 eyes (92.3%). The remaining eye underwent cyclocryocoagulation. One eye experienced secondary graft failure 12 months

postoperatively and underwent successful repeat DSAEK. One of the phakic eyes developed lenticular opacity, but the patient declined further surgery. To date, there have been no obvious signs of immunologic endothelial rejection in any eye.

## DISCUSSION

PATIENTS WITH BUPHTHALMOS INVARIABLY HAVE COMPLICATED past ocular histories, and have typically undergone multiple interventions to control and treat the disorder.

**TABLE.** Demographics, Previous Ocular Interventions, and Outcomes of Descemet Stripping Automated Endothelial Keratoplasty in Buphthalmic Eyes

Case	Patient	Age	Eye	Comorbidities	Previous Surgeries <sup>a</sup>	Lens	BSCVA Preop	BSCVA Postop	F/U (mo)	ECL %
1	A	15	OD	G	Gs3, L1	A	HM	20/400	42	53.1
2	A	15	OS	G	Gs2, L1	A	HM	20/200	36	42.8
3	B	39	OD	G	Gs4, L1, Cs1	A	CF	20/200	24	48.2
4	C	45	OS	G, ROP	Gs6, L1, R22	A	CF	CF	— <sup>b</sup>	— <sup>b</sup>
5	C	45	OS	G, ROP	Gs6, L1, R22	A	CF	20/100	18	n/a
6	D	30	OS	G	Gs2	P	CF	20/32	48	41.5
7	E	31	OD	G, C	Gs2	P <sup>c</sup>	20/60	20/28	6	23.7
8	F	32	OD	Am	Gs3, L1	P	CF	CF	24	28.2
9	G	33	OS	G, Am	Gs2	P	CF	20/40	12	51.0
10	H	36	OD	G, Am	Gs2, Cs1	P	CF	20/60	6	40
11	I <sup>d</sup>	33	OS	G	Gs3, Cs2	PCIOL	HM	20/60 <sup>d</sup>	12	— <sup>d</sup>
12	I	33	OS	G	Gs3, Cs3	PCIOL	HM	20/100	6	40.7
13	J	36	OS	G	Gs3, L1	PCIOL	CF	20/16	24	36.5
14	K	54	OS	G	Gs3, L1	PCIOL	20/70	20/25	24	39.9

A = aphakic; Am = amblyopia; BSCVA = best spectacle-corrected visual acuity; C = cataract; CF = count fingers; Cs = corneal surgery; DSAEK = Descemet stripping automated endothelial keratoplasty; ECL = endothelial cell loss; F/U = follow-up; G = glaucoma; Gs = glaucoma surgery; HM = hand movements; L = lens surgery; P = phakic; PCIOL = posterior chamber intraocular lens; R = retinal surgery; ROP = retinopathy of prematurity.

<sup>a</sup>Numbers in the "Previous surgeries" column specify how many procedures of each type of intervention had been previously performed in each eye.

<sup>b</sup>Primary failure; graft failed to attach despite repeat rebubbling (see "Results" section).

<sup>c</sup>Case number 7 underwent combined DSAEK and phacoemulsification with posterior chamber IOL implantation.

<sup>d</sup>Endothelial failure occurred 12 months after DSAEK; BSCVA in this case refers to the value recorded before failure.

Visual prognosis often is guarded because of ocular comorbidities, including glaucomatous optic neuropathy and amblyopia. When vision decreases from the patient's baseline because of corneal edema secondary to endothelial failure and/or when symptoms of bullous keratopathy occur, intervention may be appropriate, despite the improbability of properly assessing visual potential.<sup>2,11</sup>

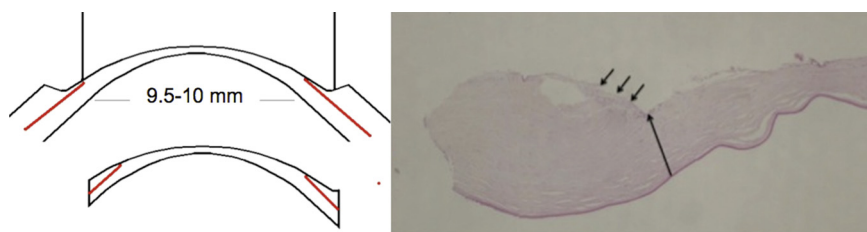
PK in patients with buphthalmos is considered to be a higher-risk procedure compared to PK performed for other indications, in terms of both intraoperative and postoperative complications.<sup>3</sup> "Open sky" surgery used in PK is more difficult in buphthalmic eyes that present with compromised structural integrity, reduced scleral rigidity, and/or increased vitreous pressure.<sup>2,5,10,11</sup> In addition, many of the factors identified by the Collaborative Corneal Transplantation Studies as the strongest predictors for graft failure after PK (young recipient age, previous corneal transplantation, history of previous anterior segment surgery, preoperative glaucoma, and quadrants of anterior synechiae) may apply to patients with buphthalmos.<sup>12</sup>

In comparison to PK, DSAEK is performed completely under "closed system" conditions via a short, beveled, clear cornea tunnel. This closed system approach effectively counteracts vitreous pressure and may prove useful if/when intraoperative complications such as suprachoroidal hemorrhage occur. Visual and symptomatic recovery is faster with DSAEK than PK, and the risk of late postoperative

suture-related complications is eliminated.<sup>2,4,5</sup> Patients with buphthalmos often have only 1 eye with visual potential by adulthood; DSAEK can minimize potential surgical complications in these eyes.

Nevertheless, only a single case of DSAEK in a buphthalmic eye has been reported in the literature to date.<sup>6</sup> One likely explanation is that the condition itself is uncommon and surgery much more complex. For example, these eyes often present with larger corneal size and grossly edematous cornea, may be phakic or aphakic, and may have undergone several previous surgeries (particularly glaucoma drainage procedures). These factors, both individually and in combination, contribute to increased surgical difficulty when performing PK.<sup>2,3</sup> Most of these conditions are also known to hinder graft attachment following DSAEK.

We attempted to determine whether DSAEK would be a suitable approach for the surgical treatment of endothelial failure in eyes with buphthalmos. In this case series, DSAEK was performed successfully in all but 1 case; in that eye, an eccentric trephination of the donor tissue was directly responsible for the failure (Figure 5). Further, the presence of Haab striae allowed the surgeon to easily identify Descemet membrane by pinching the fold and performing a descemetorhexis (Figure 1). We found the posterior corneal surface beneath the striae to be consistently smooth in all patients, thus permitting the same type of graft adherence as in nonbuphthalmic eyes. We



**FIGURE 5.** Schematic diagram and histologic finding of a large donor trephination. (Left) Large eccentric trephination of donor tissue for Descemet stripping automated endothelial keratoplasty may lead to inclusion of the thick, peripheral undissected stroma. (Right) Histologic analysis in this case shows the presence of a peripheral gutter between a sickle of thick undissected tissue (left of the large arrow) and the microkeratome-dissected surface (right of the large arrow), with inclusion of surface epithelium (small arrows). Magnification 40X.

used donor grafts 9.5-10.5 mm in diameter to match the increased corneal size and enlarged area of decompensated endothelium, as previous experience with PK recommends.<sup>3</sup> The manual dissection of the residual peripheral donor anterior stroma was achieved while the tissue was still mounted on the artificial anterior chamber (Figure 2). This technique provided a large area of at least 11 mm in diameter from which the donor disc could be obtained. Despite this, in 1 case a 10.5-mm donor graft included a peripheral sickle of nondissected tissue, which prevented attachment. This complication may be more frequent in very large donor grafts, even with minor decentration of the punch. We therefore recommend these large grafts be reserved for use in exceptional cases. We further recommend donor tissue be dissected peripherally up to a 12-mm diameter, thus enabling the dissection plane to reach the corneoscleral limbus.

Five eyes in this series were phakic. One had cataract and underwent combined DSAEK with lens extraction and insertion of intraocular lens. The remaining 4 eyes had clear lenses, requiring modification to our standard technique for DSAEK. For phakic patients, many corneal surgeons elect to perform cataract surgery prior to or concurrently with DSAEK. There are, however, some phakic patients that are likely to benefit from DSAEK without cataract surgery, in particular children and younger adults with clear crystalline lenses and normal accommodative function. For these 4 cases, we found the surgical modification equally as effective as in nonbuphthalmic phakic eyes.<sup>10</sup> Cataract surgery in eyes that have undergone DSAEK requires little deviation from standard phacoemulsification technique; however, the 1 patient in our series who did sustain traumatic cataract declined to undergo this additional procedure. For the aphakic eyes, other modifications such as transcorneal hitch suture were also found to be effective.<sup>8</sup>

All corneas were clear by 1 month postoperatively, with the exception of the primary graft failure as discussed above. Graft detachment occurred in 1 other case and was managed successfully. Our results suggest DSAEK can be performed in buphthalmos with the same success

rate as in eyes with different indications. In our series, 2 of 14 grafts (14.3%) failed during an average follow-up of 33.3 months. This compares favorably with a recently published series of patients with buphthalmos that showed a 60% failure rate an average 28.6 months postoperatively with full-thickness grafts.<sup>3</sup>

Long-term survival of DSAEK grafts is lower in glaucomatous eyes, especially in eyes that have required drainage procedures.<sup>13-15</sup> In our series, only 1 graft failed 12 months after DSAEK surgery. This case underwent a successful second DSAEK and the graft has remained clear to date. It has been reported that small grafts in buphthalmos fail more often.<sup>3</sup> Transplanted endothelial cells migrate over the graft-host junction to the recipient rim<sup>16</sup>; the fewer number of transplanted endothelial cells in small-sized grafts migrating over to the relatively larger-sized recipient rim in buphthalmos has been thought to be responsible for graft failure in PK grafts.<sup>3</sup> Toker and associates recommended adjusting the graft size in each eye before PK surgery.<sup>3</sup> This may explain the decreased incidence of graft failure in our series, but we acknowledge that a longer follow-up is needed to confirm our short-term results.

Eyes with multiple comorbidities often have poor visual prognosis after corneal transplantation. In our series, however, BSCVA improved in all but 2 eyes, with 84.6% achieving BSCVA of 20/400 or better and 38.5% achieving BSCVA of 20/40 or better. Further, 11 of the eyes (84.6%) reached their maximum BSCVA within 3 months, indicating the visual potential is rapidly achieved in DSAEK procedures for this disorder. In contrast, Toker and associates<sup>3</sup> reported a final postoperative BSCVA of 20/400 or better in 70% of eyes with buphthalmos that underwent full-thickness PK, and a BSCVA of 20/40 or better in only 2 eyes (10%) at last follow-up.

Endothelial cell (EC) loss following DSAEK ranges from 24%-61% at 12 months, with a mean of 43%.<sup>4,5</sup> The mean EC loss in our series fell within this range, although the EC loss was higher than the values recorded in our patients undergoing DSAEK for other indications. The reasons for this increase are probably multifactorial, as surgery is more difficult in buphthalmic eyes, and consequently

iatrogenic cell loss could be higher. Further, donor tissue used for this indication—despite being larger than is typical—is relatively small when compared to the surface area of the whole buphthalmic cornea. We know endothelial cells migrate from areas of high endothelial cell density to areas of low density.<sup>16</sup> In buphthalmic eyes with totally decompensated endothelium, this migration is expected to take place from the DSAEK graft into the peripheral host cornea, thus potentially reducing the central endothelial cell count. Terry and associates have recently shown no difference in post-DSAEK EC loss among groups of eyes receiving grafts of different sizes,<sup>17</sup> but his series concentrated on eyes with Fuchs dystrophy. Those with moderate to mild edema, in particular, retain a relatively good reservoir of EC in the peripheral cornea, which can still function efficiently all around the DSAEK graft and block EC migration. Finally, previous glaucoma surgery, whether simple filtering procedures or implantation of stents/shunts, is known to increase postoperative EC loss in eyes undergoing DSAEK.<sup>13–15</sup>

In our series, glaucoma progressed in 1 eye. Because of the advanced stage of glaucoma in most of our cases in this series, particular care was taken to avoid pupillary block in the early postoperative period. Persistent epithelial

defects rarely occur following DSAEK and surface toxicity is consequently less problematic, thus allowing preoperative glaucoma medication regimens to remain unaltered. In post-PK buphthalmic eyes, worsening glaucoma control is frequent; almost half the cases in 1 published report (9 of 20 eyes; 45%) required repeat cyclo-destructive procedures.<sup>3</sup>

Because of the rarity of buphthalmos, and the even less common occurrence of endothelial failure in this population group, meaningful trials comparing the risks and benefits of PK and DSAEK are unlikely to be undertaken. Best clinical judgment needs to be applied in combination with detailed discussion with the patient and informed consent. In our experience, DSAEK performed in eyes with buphthalmos reduces intraoperative and postoperative risks. Corneal clarity is rapidly achieved with minimal disturbance to an often already disorganized anterior segment. Following DSAEK, postoperative refractive error is minimized, and visual potential is rapidly achieved.

These advantages are overwhelming, and, although further studies are required to determine the long-term graft survival and effect on control and progression of glaucoma in buphthalmic eyes, we believe that DSAEK is a viable surgical technique to treat eyes with buphthalmos.

---

ALL AUTHORS HAVE COMPLETED AND SUBMITTED THE ICMJE FORM FOR DISCLOSURE OF POTENTIAL CONFLICTS OF INTEREST. Massimo Busin received travel expense reimbursement and royalties from Moria (Antony, France). The study was not funded by any source. Contributions of authors: All authors have contributed to the conduct of the study, including collection, analysis, and interpretation of data. M.B. supervised and approved the final version.

---

## REFERENCES

- Idrees F, Fraser SG, Sowden JC, Khaw PT. A review of anterior segment dysgenesis. *Surv Ophthalmol* 2006;51(3): 213–231.
- Vanathi M, Panda A, Vengayil S, Chaudhuri Z, Dada T. Pediatric keratoplasty. *Surv Ophthalmol* 2009;54(2):245–271.
- Toker E, Seitz B, Langenbucher A, Dietrich T, Naumann GO. Penetrating keratoplasty for endothelial decompensation in eyes with buphthalmos. *Cornea* 2003; 22(3):198–204.
- Lee WB, Jacobs DS, Musch DC, Kaufman SC, Reinhart WJ, Shtein RM. Descemet's stripping endothelial keratoplasty: safety and outcomes: a report by the American Academy of Ophthalmology. *Ophthalmology* 2009;116(9):1818–1830.
- Anshu A, Price MO, Tan DT, Price FW. Endothelial keratoplasty: a revolution in evolution. *Surv Ophthalmol* 2012;57(3): 236–252.
- Unterlauff JD, Weller K, Geerling G. A 10.0 mm posterior lamellar graft for bullous keratopathy in a buphthalmic eye. *Cornea* 2010;29(10):1195–1198.
- Busin M, Bhatt PR, Scorcia V. A modified technique for Descemet membrane stripping automated endothelial keratoplasty to minimize endothelial cell loss. *Arch Ophthalmol* 2008;126(8):1133–1137.
- Patel AK, Luccarelli S, Pozin D, Busin M. Transcorneal suture fixation of posterior lamellar grafts in eyes with minimal or absent iris-lens diaphragm. *Am J Ophthalmol* 2011;151(3): 460–464.
- Price FW Jr, Price MO. Descemet's stripping with endothelial keratoplasty in 200 eyes: early challenges and techniques to enhance donor adherence. *J Cataract Refract Surg* 2006; 32(3):411–418.
- Busin M, Beltz J, Scorcia V. Descemet-stripping automated endothelial keratoplasty for congenital hereditary endothelial dystrophy. *Arch Ophthalmol* 2011;129(9): 1140–1146.
- Al-Ghamdi A, Al-Rajhi A, Wagoner MD. Primary pediatric keratoplasty: indications, graft survival, and visual outcomes. *J AAPOS* 2007;11(1):41–47.
- Maguire MG, Stark WJ, Gottsch JD, et al. Risk factors for corneal graft failure and rejection in the collaborative corneal transplantation studies. Collaborative Corneal Transplantation Studies Research Group. *Ophthalmology* 1994;101(9): 1536–1547.
- Armitage WJ, Dick AD, Bourne WM. Predicting endothelial cell loss and long-term corneal graft survival. *Invest Ophthalmol Vis Sci* 2003;44(8):3326–3331.
- Anshu A, Price MO, Price FW Jr. Descemet stripping endothelial keratoplasty: long-term graft survival and risk factors

- for failure in eyes with preexisting glaucoma. *Ophthalmology* 2012;119(10):1982–1987.
15. Price MO, Fairchild KM, Price DA, Price FW Jr. Desce-met's stripping endothelial keratoplasty: five-year graft survival and endothelial cell loss. *Ophthalmology* 2011; 118(4):725–729.
  16. Imaizumi T. Movement of corneal endothelium after pene-trating keratoplasty. Observation of sex chromatin as a cell marker. *Nihon Ganka Gakkai Zasshi* 1990;94(10):928–936.
  17. Terry MA, Li J, Goshe J, Davis-Boozer D. Endothelial kerato-plasty: the relationship between donor tissue size and donor endothelial survival. *Ophthalmology* 2011;118(10):1944–1949.





### **Biosketch**

Dr Jacqueline Beltz is Staff Specialist on the Corneal Unit, Royal Victorian Eye and Ear Hospital, Australia. She is Deputy Director of the Lions Eye Donation Service, and has an appointment at the Centre For Eye Research Australia, University of Melbourne. Following corneal fellowships with Professors Rasik Vajpayee in Australia and Massimo Busin in Italy, Dr Beltz has maintained keen interest in lamellar corneal transplantation. She enjoys clinical practice and research in this field.